

# Mapping of the snuffbox and cubital vessels for percutaneous Arterial Venous Fistula (pAVF) in dialysis patients

Jeffrey E. Hull<sup>1</sup>, Emily N. Kinsey<sup>2</sup>, Wendy L. Bishop<sup>1</sup>

<sup>1</sup>Richmond Vascular Center, North Chesterfield, VA - USA

<sup>2</sup>University of Virginia Medical School, Charlottesville, VA - USA

## ABSTRACT

**Purpose:** Report on the anatomic qualification of the snuffbox radial artery (SBRA) and proximal radial artery (PRA) for pAVF. **Methods:** Retrospective analysis of upper extremity mapping in 64 limbs in 55 dialysis patients was performed. The radial artery was assessed for diameter, patency, flow and proximity to the adjacent vein to SBRA and PRA. Sites qualified for pAVF on a binary basis when the in situ radial artery and adjacent vein were straight, parallel, greater than 2 mm in diameter and within 1.5 mm of each other. Effect of age, sex, diabetes, systolic blood pressure and obesity were assessed with logistic regression. Mean, median and frequency distribution of vessel diameter and distance were analyzed.

**Results:** Radial artery sites were qualified for pAVF in 47.6% (30/63) at the SBRA and 87.9% (29/33) at the PRA. SBRA sites were disqualified for vessel size in 36.4% (12/33 overall, usually vein 11/12), distance in 24% (8/33) and both 36.4% (12/33). All (4/4) PRA sites were disqualified for vessel size alone. The adjacent vein was the median vein or cephalic vein for the SBRA, and the perforating vein or vena comitans for the PRA. Effects of age, sex, diabetes, systolic blood pressure, obesity and prior fistula did not attain statistical significance.

**Conclusions:** Most dialysis patients meet the anatomic requirements for pAVF in the SBRA or PRA. Vessel size is the most common limiting variable followed by distance between vessels.

**Key words:** Arteriovenous shunt, Surgical, Brachiocephalic veins, Radial artery, Renal dialysis, Ultrasonography

Accepted: October 21, 2012

## INTRODUCTION

The arterial venous fistula (AVF) is the preferred vascular access for the growing number of hemodialysis patients worldwide (1). Early referral and pre-operative vein mapping leads to an increased incidence of AVF use that results in decreased early mortality (2). Failure to mature is one of the major problems associated with AVF (3). Techniques that would provide a consistent AVF maturation would have a significant impact on fistula prevalence.

Early animal experience using a novel percutaneous technique for AVF creation that provides a consistent geometry to the anastomosis was recently reported. (abstract Hull; VASA 2012, Orlando, FL, USA). The anastomotic configuration provided by this technique is similar to a recently described surgical procedure for AVF creation - the piggyback straight line onlay technique (pSLOT), which has promise to decrease the incidence of early AVF failure and increase maturation (4). The ability to perform such an anastomosis percutaneously has the potential to make a significant impact on

the ease of AVF creation and maturation.

The pAVF technique requires a feeding artery and outflow vein straight and parallel to each other in close proximity (<1.5 mm) with a diameter greater than or equal to 2.0 mm. The radial artery is ideal for the creation of the pAVF as it has a wide safety profile (5). Two anatomic sites in the forearm used for fistula creation offering these anatomic features, working distal to proximal as recommended by KDOQI guidelines, are the distal radial artery in the anatomic snuffbox and the proximal radial artery at the elbow (6,7). The purpose of this study was to assess the prevalence of anatomy suitable for creation of pAVF in these two sites.

## MATERIALS AND METHODS

A retrospective chart and image review of vein mapping and fistula mapping studies of end-stage renal disease (ESRD) patients was performed. A total of 68 consecutive ESRD patient limbs were assessed between January 2012 and June 2012. Four limbs were not included in the analysis because

of lack of data at both the snuffbox and the proximal radial artery. Patient demographics are listed in Table I. The Institutional Review Board (IRB) at Chippenham-Johnston Willis Hospital in Richmond, Virginia, USA approved this study and allowed waiver of informed consent for this study.

Sixty-four limbs were included in the analysis. For vein mapping patients, bilateral upper extremity vessels were assessed for diameter and condition. In patients with arterial venous fistulas in place who were undergoing fistula mapping, only the ipsilateral extremity was studied. Vein mapping was performed in 19 limbs on 10 patients without existing fistula or graft. Vein and fistula mapping was performed in 40 limbs on 40 patients with fistulas, and five limbs in five patients with grafts.

Mapping was performed with SonoSite M-turbo (SonoSite, Inc., Washington) typically with a linear 5-7 MHz transducer. Our standard upper extremity mapping protocol is a modification of the Society of Vascular Ultrasound guidelines (8). Modifications include median vein assessment, artery and vein diameter measurements and intra-vessel distances in the anatomic snuffbox, the antecubital fossa and ad hoc sites where forearm artery and veins are in close proximity. As noted in definitions below the median cubital vein was more precisely defined as the median basilic and/or the median cephalic vein.

Data extracted from our standard mapping protocol includes upper extremity artery and vein diameter and condition, radial artery and the adjacent vein condition, diameter, proximity, and relative orientation at the snuffbox, wrist and antecubital fossa. In AV fistulas data included diameter, velocity, flow volume and condition at the anastomosis; the proximal, mid and distal venous outflow; the proximal, mid and distal arterial inflow, and artery distal to anastomosis.

**Definitions**

Patent vessel: Vessels were considered patent if they were free of calcification, stenosis, thrombosis, or occlusion.

**TABLE I - PATIENT DEMOGRAPHICS. AGE, BMI AND SYSTOLIC BP ARE EXPRESSED AS MEAN ± STANDARD DEVIATION**

Diabetes	26 (51%)
IDDM	8 (30.8%)
NIDDM	18 (69.2%)
Sex	
Male	34 (61.8%)
Female	21 (38.2%)
Age	65.0 ± 14.8; range 29-90
BMI	28.5 ± 7.3
Systolic BP	148 ± 24.1

BMI, body mass index; BP, blood pressure; IDDM, insulin-dependent diabetes mellitus; NIDDM, noninsulin-dependent diabetes mellitus

Distance between vessels: The distance between artery and vein was measured where the vessels were demonstrated closest together on longitudinal or transverse images.

Parallel vessels: Vessels were considered parallel when the angle between the artery and vein intersection was less than 30 degrees.

Proximal radial artery: The first two centimeters of the radial artery distal to the brachial artery bifurcation.

Snuffbox radial artery: Distal radial artery after passing beyond the extensor pollicis brevis tendon.

Median cephalic vein: Superficial vein in antecubital fossa connecting cephalic vein to median vein.

Median basilic vein: Superficial vein in antecubital fossa connecting the basilic vein to the median vein. This vein is often referred to as the median cubital vein; however, this description is inadequate for our use as there are numerous variations at the elbow.

Perforating vein: Vein in antecubital fossa connecting the deep and superficial vessels. Typically, joining the deep brachial veins and vena comitans to the junction of the median cephalic, median basilic, and median vein of the forearm.

Median vein: Superficial vein in the forearm draining into the median basilic and median cephalic vein, and communicating with the perforating vein.

Cephalic vein: In the forearm this vessel drains from the wrist into the upper arm cephalic vein.

Anatomic candidate for pAVF: Criteria to be considered a candidate suitable for pAVF included the following: in situ radial artery greater than or equal to 2 mm in diameter, adjacent vein greater than or equal to 2 mm in diameter, and distance between artery and adjacent vein less than or equal to 1.5 mm.

**Statistical analysis**

Summary Statistics calculated include the mean, median and standard deviation for size and distance between vessels at the perforating vein, distal brachial vein, cephalic vein and/or medial vein at the wrist and snuffbox. Binary data of whether or not qualified for pAVF fistula at the SBRA and PRA was assessed. Demographic data was compared to binary qualification at the SBRA and the PRA with logistic regression. Statistical analyses were performed using MedCalc for Windows, version 12.3.0.0 (MedCalc Software, Mariakerke, Belgium).

**RESULTS**

A total of 64 limbs were assessed in 55 patients. Data for the snuffbox vessels was available in 63 limbs, and for the cubital vessels in 33 limbs and from both sites in 29 limbs. Overall, limbs meeting anatomic cri-

teria for pAVF were 47.6% (30/63) at the snuffbox radial artery and 87.9% (29/33) at the PRA. In the 29 limbs assessed at both the snuffbox and the cubital vessels 96.6% (28/29) qualified in at least one site, 55.2% (16/29) qualified at both, 41.4% (12/29) at PRA only, none at SBRA only.

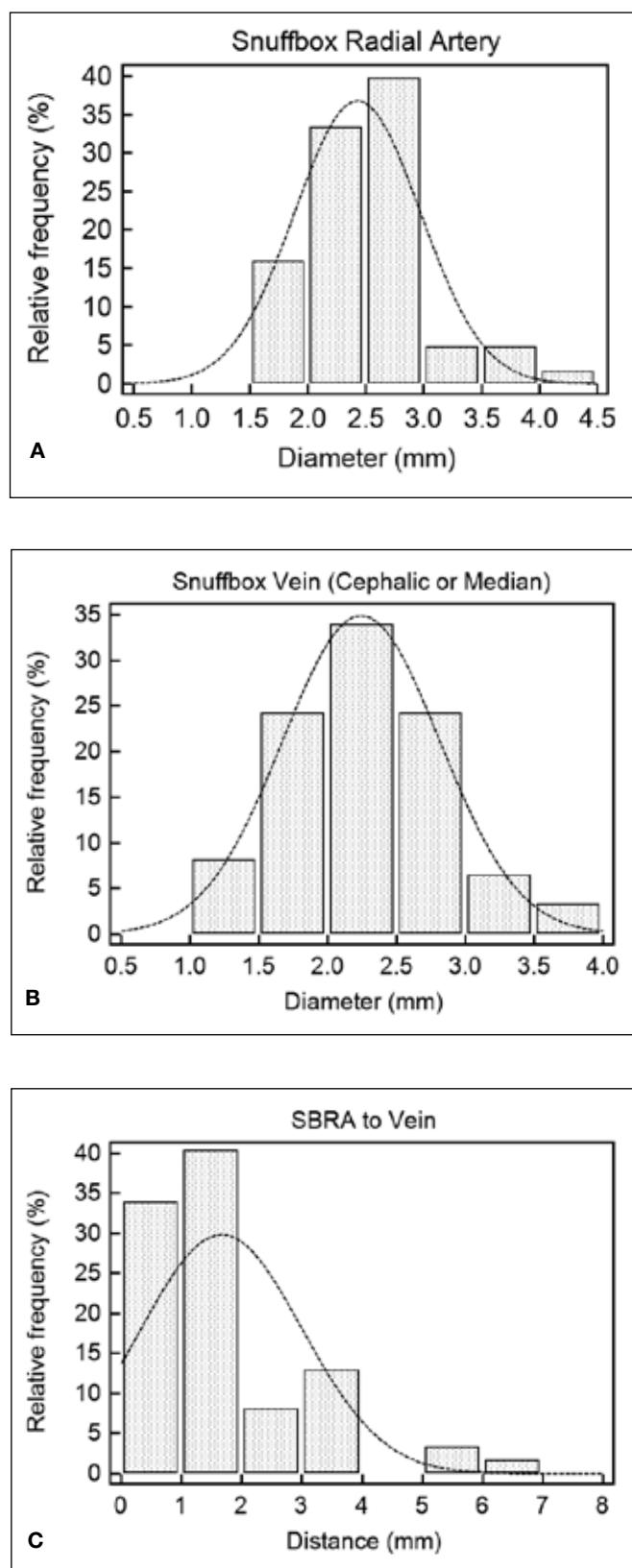
Age, sex, diabetes, systolic blood pressure and obesity did not have a statistically significant effect on the presence of qualifying anatomy at the snuffbox radial artery and PRA.

A total of 90.0% (36/40) of existing fistulas were at the elbow of patients and 10.0% (4/40) of fistulas were in a more distal location. The artery used in the fistula was the brachial artery in 87.5% (35/40), and the radial artery in 12.5% (5/40) of fistulas (distal radial artery in four and proximal radial artery in one). All grafts (5/5) were in the brachial artery. The site of the access was on the left in 66.7% of patients (30/45) and located on the right side in 33.3% (15/45).

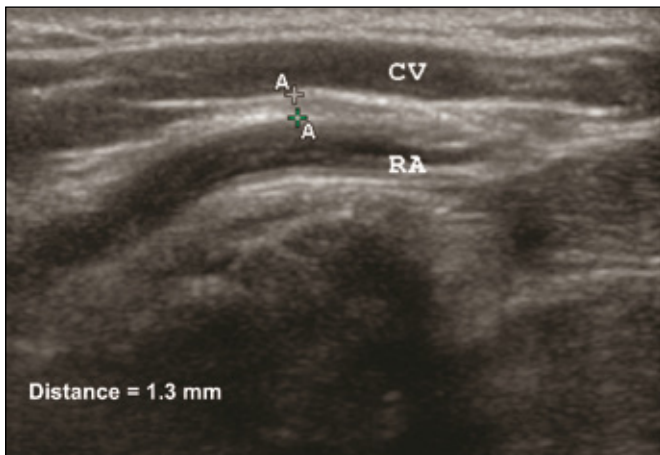
*Snuffbox radial artery*

Of the 63 total limbs that had anatomy assessed at the snuffbox, 47.6% (30/63) were considered suitable for AVF by meeting the aforementioned criteria. The median diameter of radial artery at the snuffbox was 2.5 mm (range 1.5-4.1; standard deviation 0.5423), and the median diameter of adjacent vein at the snuffbox was 2.3 mm (range 1.1-3.8; standard deviation 0.5719). The vein found at the snuffbox was either the cephalic or median vein. The median distance between the radial artery and adjacent vein at the snuffbox was 1.3 mm, with a standard deviation of 1.3362, and range 0.09 to 6.9. The frequency distributions of SBRA diameter, the adjacent cephalic or median vein diameter, and distance between the vessels is shown in Figure 1.

The most common reason for disqualification at the snuffbox was the small size of vessels, seen in 36.4% (12/33) of the limbs which did not qualify. Other reasons for disqualification at the snuffbox included distance alone 24% (8/33), distance and size of the vein 33% (11/33), distance and size of the artery (one patient), and all three criteria (one patient). Of the 45 patients who had access already in place, one did not have measurements taken at the snuffbox. The other 44 patients had values recorded for snuffbox measurements, and 47.7% (21 of 44) patients qualified for AVF at this site. All 19 limbs assessed by vein mapping studies had measurements taken at the snuffbox. At this location, 47.4% (9/19) fistula-naïve patients met all three criteria. The difference in qualifying at the snuffbox in those with a fistula in place compared to fistula-naïve patients was not statistically significant (P=0.9795). Figure 2 is a longitudinal ultrasound image of the snuffbox in a patient who qualified for the pAVF; this image reveals relatively straight and parallel vessels.



**Fig. 1** - Distance between the radial artery and adjacent vein at the snuffbox. This graph shows that 66.1% of distances were less than or equal to 1.5 mm.



**Fig. 2** - Ultrasound Image: A longitudinal view of the radial artery and adjacent vein at the snuffbox. CV, Cephalic Vein; RA, Radial Artery; A-A distance = 1.3 mm.

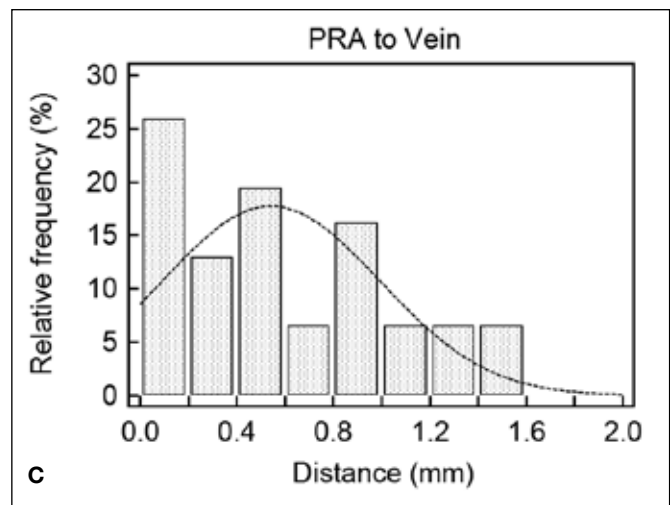
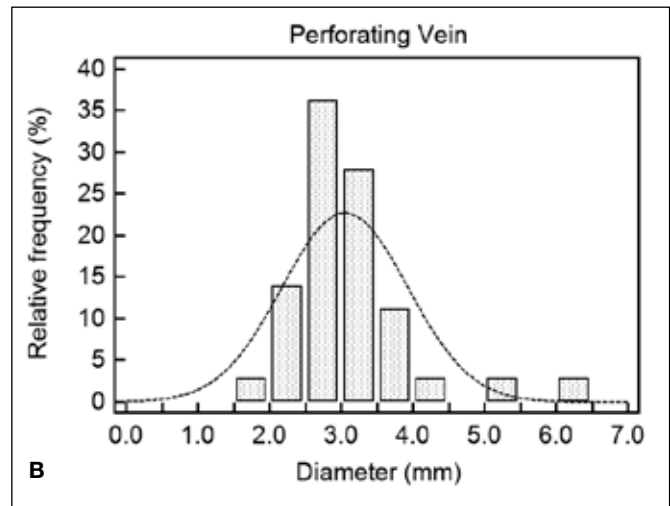
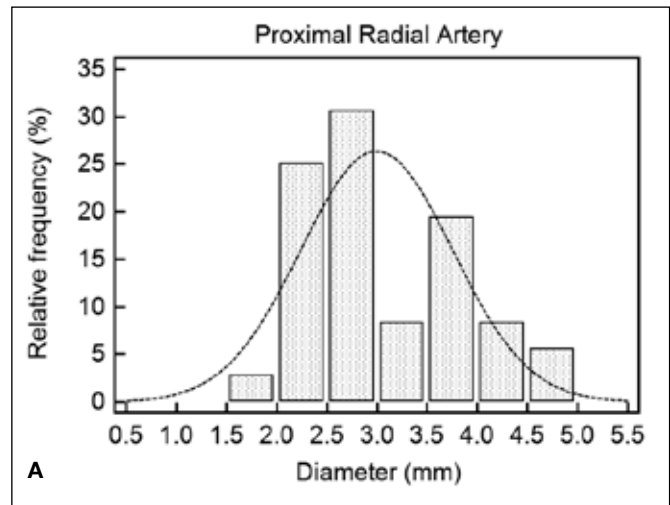
*Proximal radial artery*

At the elbow, 87.9% (29/33) patients were considered suitable for the pAVF. The median diameter of the proximal radial artery was 2.8 mm (range 1.8 to 4.8; standard deviation 0.6354). The median vein diameter was 2.9 mm (range 1.7 to 6.4; standard deviation 0.8775). The median distance between the proximal radial artery and adjacent vein was 0.50 mm, with a standard deviation of 0.4493, and range 0 to 1.4 mm. The frequency distributions of the PRA diameter, the adjacent perforating vein or vena comitans diameter, and distance between the vessels are shown in Figure 3.

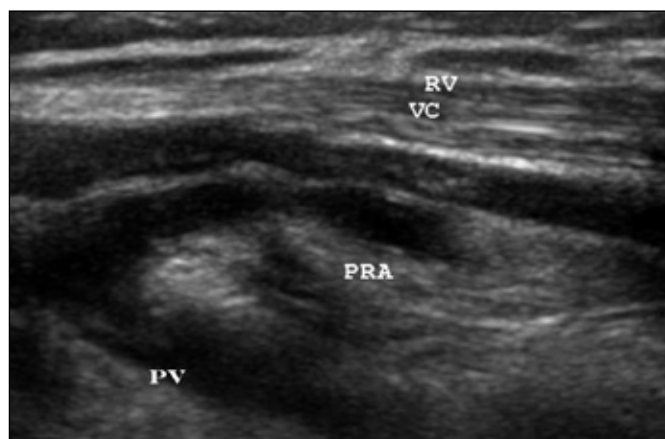
Of the patients with access that did not have suitable anatomy at the proximal radial artery, two of the four limbs had vessels less than 2 mm in diameter, and in two out of four limbs the vessels were not seen. The distance between the proximal radial artery and adjacent vein was never greater than 1.5 mm, and thus distance was never the reason for disqualification at the proximal radial artery. Having a fistula did not significantly affect the presence of qualifying anatomy at the PRA (P=0.9711). Of the eight limbs that were fistula naïve, seven (87.5%) had suitable anatomy at the proximal radial artery. The criteria were met in 88.0% (22/25) patients who already had fistulas in place. Figure 4 is an ultrasound image of a patient with suitable anatomy at the proximal radial artery.

**DISCUSSION**

The pAVF is a novel concept under development in the animal model (abstract Hull; VASA 2012, Orlando, FL, USA). The pAVF catheter system uses peripheral venous access with placement of a 7 French sheath in a superficial arm vein under ultrasound guidance. From the venous access a penetrating catheter is advanced from the



**Fig. 3** - Distance between the proximal radial artery and adjacent vein at the elbow. This graph shows that 100% of the values for distance at the proximal radial artery were less than or equal to 1.5 mm.



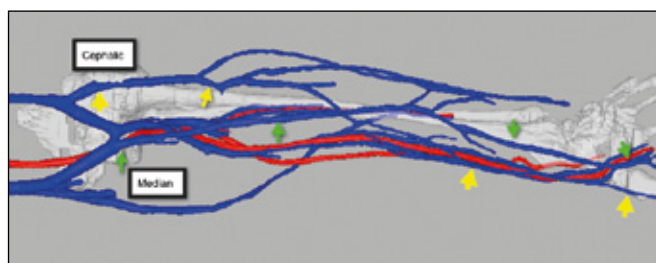
**Fig. 4** - Proximal radial artery PRA is shown between the vena comitans VC and perforating vein PV.

vein into the adjacent artery. A tissue welding catheter is advanced into the artery. The artery and vein are compressed, welded together, and side-to-side elliptic anastomosis is created between vessels in close proximity, and relatively straight and parallel. The catheter is withdrawn and venous occlusion or hemostasis is obtained at the access site. This procedure is performed in the animal model with ultrasound guidance in approximately 10 minutes. For the pAVF to be used in humans, suitable sites for the procedure need to be defined.

The current anatomic study demonstrates the potential for pAVF creation in humans using the snuffbox radial artery in 47.6% of patients and proximal radial artery in 87.9% patients requiring dialysis. In the subset of 29 patients with data from the snuffbox and the cubital vessels, 96.6% met the anatomic criteria. The significance of this finding is threefold. One is that the anatomy required for the pAVF is present in sufficient dialysis patients to make the pAVF a viable technology. The second is that these sites are also suitable for the surgical pSLOT fistula. The third is that in our local practice we may have overlooked the SBRA and PRA as sites for fistulas.

The radial artery is our proposed donor artery for the pAVF for safety reasons including its anatomy with respect to collateral flow and the course of the radial nerve, as well as a robust history of use in AVF, CABG and catheter procedures. In a recent study of 10,676 trans radial cardiac procedures the access failure rate without imaging guidance was 4.9% and the vascular complication rate was 0.4% (5). Radial related vascular complications occurred in 44 patients and included vessel perforation, arterial venous fistula (nine of the 44 complications), pseudo aneurysm, dissection, compartment syndrome and local hematoma (none requiring transfusion).

The use of the radial artery in the forearm for AVF at our prescribed sites could result in ideal geometry for potential long-term patency of the pAVF. The ves-



**Fig. 5** - 3D reconstruction of upper arm magnetic resonance angiogram with gadafoveset trisodium contrast (Ablavar®, Lantheus Medical Imaging, Billerica, MA, USA). Cephalic vein marked with yellow arrows and median vein marked with green arrows. Note that the median vein is adjacent to the SBRA while the cephalic vein is adjacent to radial artery at the wrist. A fistula at the SBRA would drain to the medial basilic, perforating and medial cephalic vein with dual outflow in the upper arm. A wrist fistula would drain into the upper arm cephalic vein and single vessel upper arm outflow.

sels are parallel, touching or within 1.5 mm of each other and are brought together without twisting and anastomosed in a side-to-side configuration. The piggy-back Straight Line Only Technique (pSLOT) describes a similar open surgical technique shown to significantly reduce juxta-anastomotic stenosis (JAS), and to reduce overall fistula failure rate from 40% to 17% when compared with standard end-to-side anastomosis (4).

The snuffbox is often overlooked as a primary AVF site. However, in one study it was used in 50% (189/376) of patients (9). Similar to our study, an anatomic cadaver study demonstrated that the SBRA and adjacent vein were present in the snuffbox in 92% (23/25) of specimens and were a mean of 4 (SD 2) mm apart (10). The greater distance between artery and vein is probably because of deflation of vessels in cadaveric specimens.

Surgical series using a proximal radial fistula at the elbow and following an algorithm using distal to proximal sites have achieved high rates of AVF creation in several reports (9,11,12). Konner reports the creation of 748 consecutive AVF with 52% at the wrist, 48% at the elbow often using the perforating vein (12). The numbers of fistulas created in the above surgical series are consistent with the numbers reported in this report with approximately 50% and 90% of patients being candidates for distal and proximal radial artery fistulas, respectively.

The proposed algorithm for the pAVF would be to create either a pAVF at the most distal anatomic site available as demonstrated by vein mapping. If the fistula matures it would be used for dialysis. If the fistula failed to mature adequately the next most distal site would have an appropriate pAVF or surgical AVF (sAVF) created. One advantage of the pAVF is that at the SBRA and PRA sites a pAVF would not necessarily interfere with many of the standard sAVF such as

the distal radiocephalic or upper arm brachial artery to basilic or cephalic vein fistulas. In one study 45% of patients were able to have wrist fistulas created after their surgical snuffbox fistula thrombosed (9). In addition, fistula creation often leads to increased flow and vessel hypertrophy.

Identification of the vein adjacent to the SBRA has caused us some confusion in terms of nomenclature. In our series we traced the adjacent vein back from the snuffbox towards the elbow and found that this vein drains into the upper arm cephalic vein without communication with the median cephalic, median basilic or perforating vein in 30% of cases. In the remaining 70% of patients we found the adjacent vein was the median vein or a vein that communicated with the median vein as depicted in surgical descriptions of forearm veins (6). We believe these two different drainage patterns may affect the maturation of fistulas and hypertrophy of the more central veins. As a result we have named a wrist vein that drains into the perforating, median cephalic or median basilic veins the "median" vein, and a wrist vein that drains into the upper arm cephalic vein the "cephalic" vein (Fig. 5). This conflicts with standard nomenclature where the vein at the wrist is the cephalic vein regardless of venous outflow (6). Future assessment of fistula outcomes will be required to show whether this is a useful distinction.

Study limitations include small sample size, single center study with retrospective analysis. The study only focused on two potential sites using the radial artery. We have noted, but not routinely assessed in our standard vein mapping protocol, other sites that would be suitable for the pAVF. In five limbs there were examples of radial artery sites other than the SBRA or PRA, that were potentially suitable for pAVF. Four out of five patients met the anatomic criteria for pAVF at these sites (80%). All sites were in the distal arm, four were located at the wrist and one was located at the mid-distal forearm. Expanding the search for sites other than the radial artery would likely yield additional potential sites such as the common ulnar artery and perforating vein and

the brachial artery and the medial basilic vein.

## CONCLUSIONS

In conclusion, the anatomy of the SBRA and PRA would theoretically support the percutaneous creation of functioning AVF in dialysis patients. The percentage of patients suitable for this procedure would be similar to those reported in surgical series, that is close to 50% at the distal radial artery and 90% at the proximal radial artery. The anatomy at the SBRA and PRA are also well suited for the surgical AVF using the pSLOT anastomosis. In our practice fistulas using the SBRA and PRA may be underutilized.

## ACKNOWLEDGEMENTS

We are grateful to Patricia Eichenlaub for her work as research coordinator.

**Financial support:** None.

**Conflict of interest:** Jeffrey Hull M.D. is co-founder and stockholder of Caymus Medical Inc.

**Meeting presentation:** Presented at VASA 2012 Meeting, Orlando, FL. May 11, 2012

**Informed consent:** Waiver of informed consent approved by CJW Hospital Institutional Review Board (IRB)

Address for correspondence:  
Jeffrey E Hull  
Richmond Vascular Center  
173 Wadsworth Drive  
North Chesterfield, VA 23236  
hull.jeffrey@gmail.com

## REFERENCES

1. Collins AJ, Foley RN, Gilbertson DT, Chen SC. The state of chronic kidney disease, ESRD, and morbidity and mortality in the first year of dialysis. *Clin J Am Soc Nephrol.* 2009;4 Suppl 1:S5-11. Epub 2010/01/09.
2. Chan KE, Maddux FW, Toloff-Rubin N, Karumanchi SA, Thadhani R, Hakim RM. Early outcomes among those initiating chronic dialysis in the United States. *Clin J Am Soc Nephrol.* 2011;6(11):2642-2649. Epub 2011/10/01.
3. Dember LM, Beck GJ, Allon M, et al. Effect of clopidogrel on early failure of arteriovenous fistulas for hemodialysis: a randomized controlled trial. *JAMA.* 2008;299(18):2164-2171. Epub 2008/05/15.
4. Bharat A, Jaenicke M, Shenoy S. A novel technique of vascular anastomosis to prevent juxta-anastomotic

- stenosis following arteriovenous fistula creation. *J Vasc Surg.* 2012;55(1):274-280. Epub 2011/11/26.
5. Burzotta F, Trani C, Mazzari MA, et al. Vascular complications and access crossover in 10,676 transradial percutaneous coronary procedures. *Am Heart J.* 2012;163(2):230-238. Epub 2012/02/07.
  6. Shenoy S. Surgical anatomy of upper arm: what is needed for AVF planning. *J Vasc Access.* 2009;10(4):223-232. Epub 2009/11/17.
  7. Foundation NK; KDOQI. KDOQI Clinical Practice Guidelines and Clinical Practice Recommendations for Diabetes and Chronic Kidney Disease. *Am J Kidney Dis.* 2007;49(2)(Suppl 2):S12-S154.
  8. Upper Extremity Vein Mapping for Placement of a Dialysis Access. [Guideline] [updated 8/10/2009]; Available from: <http://www.svunet.org/files/positions/0809-upper-extrem-vein-map.pdf> Accessed 7/5/2012.
  9. Wolowczyk L, Williams AJ, Donovan KL, Gibbons CP. The snuffbox arteriovenous fistula for vascular access. *Eur J Vasc Endovasc Surg.* 2000;19(1):70-76. Epub 2000/03/09.
  10. Lirk P, Keller C, Colvin J, et al. Unintentional arterial puncture during cephalic vein cannulation: case report and anatomical study. *Br J Anaesth.* 2004;92(5):740-742. Epub 2004/03/09.
  11. Jennings WC. Creating arteriovenous fistulas in 132 consecutive patients: exploiting the proximal radial artery arteriovenous fistula: reliable, safe, and simple forearm and upper arm hemodialysis access. *Arch Surg.* 2006;141(1):27-32; discussion Epub 2006/01/18.
  12. Konner K, Hulbert-Shearon TE, Roys EC, Port FK. Tailoring the initial vascular access for dialysis patients. *Kidney Int.* 2002;62(1):329-338. Epub 2002/06/26.